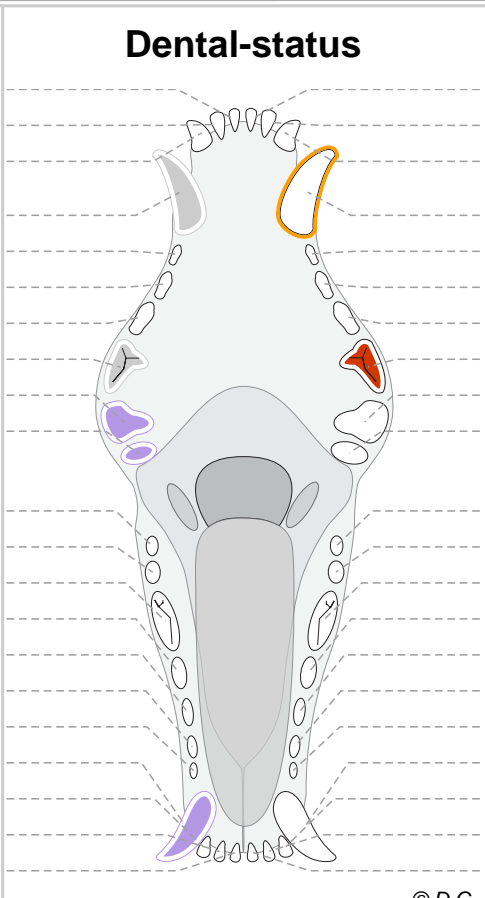




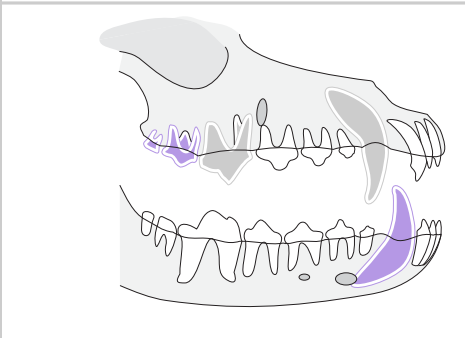
Tierärztliche Praxis Dr. Gerhard Seifert
 Wiesenstr. 1
 71131 Jettingen
 Tél. : 07452 76166
 Fax : 07452 77784
 e-mail : info@seifert-jettingen.de

Datum: 12.02.15
 Tiername: Brösel
 Besitzer: Beispiel Schönes

E	F	A	P	EX	
					101 (I1)
					102 (I2)
					103 (I3)
X					104 (C)
					105 (P1)
					106 (P2)
					107 (P3)
X					108 (P4)
				X	109 (M1)
				X	110 (M2)
Rechts					
					411 (M3)
					410 (M2)
					409 (M1)
					408 (P4)
					407 (P3)
					406 (P2)
					405 (P1)
				X	404 (C)
					403 (I3)
					402 (I2)
					401 (I1)

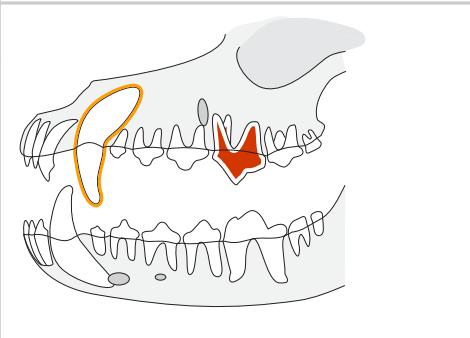


	E	F	A	P	EX	
						201 (I1)
						202 (I2)
						203 (I3)
	2					204 (C)
						205 (P1)
						206 (P2)
						207 (P3)
			X			208 (P4)
						209 (M1)
						210 (M2)
Links						
						311 (M3)
						310 (M2)
						309 (M1)
						308 (P4)
						307 (P3)
						306 (P2)
						305 (P1)
						304 (C)
						303 (I3)
						302 (I2)
						301 (I1)



Legende

- E ■ Entzündungsindex (0-3)
- F ■ Fehlender Zahn
- A ■ Fracturierten Zahn
- P ■ Persistierender Milchzahn
- EX ■ Extraktion



Verzahnung: Vorbiss
Zahnstein-Grad: ++

General Notes:

Befunde:

